NEBRASKA EQUINE
VETERINARY CLINIC

10261 County Road P38A ~ OMAHA, NE 68142
PHONE: 402-533-1151 ~ FAX: 402-533-1159
Email: office@nebraskaequine.com
Michael J. Black D.V.M.
Michael P. Thomassen D.V.M.
Kimberly N. Conover D.V.M.

Is Your Horse's Foot Balanced?

It is well recognized that the front feet are the most common source of front leg lameness. Thus it would make sense to pay particular attention in maintaining a healthy foot to try and help avoid foot lameness if possible. The following paragraphs, written by Dr. Scott Morrison a veterinarian/farrier at Rood and Riddle Equine Hospital in Lexington Kentucky, describe the form and function of the foot, giving us insight on the importance of proper foot balance, loading, and stress.

> "The foot receives the initial forces generated during ground impact. A healthy foot significantly dampens the vibrations generated during ground impact. The heel region in particular is designed for this purpose and houses the structures most responsible for absorbing shock such as the frog, digital cushion, collateral cartilages, bars and an extensive vascular system. All these structures work together in harmony to absorb and dissipate shock. Therefore, for the heel to accommodate this task it needs to have healthy and fully functional structures.
>
> At higher speeds, when shock absorption is most needed, the heel should contact the ground first. The phases of the stride and foot loading sequence should be a coordinated pattern of heel contact, loading, break-over etc.. Those which land toe first, don't utilize the heel to absorb shock and as a result commonly present with lameness issues further up the limb. Horses with low heels and long toes appear to be prone to toe first landing. These cases typically have a negative palmer/plantar angle of the distal phalanx relative to the ground. Repetitive toe first landing is an inefficient and potentially damaging landing pattern. The normal foot loading pattern is out of sequence. It can be seen in horses that are fatigued or lazy and don't fully extend the shoulder, it can also be seen in the long toe, low heel syndrome or in cases which have preexisting heel pain and land on the toe in an effort to protect the heel. It is however, normal for horses to land toe first when landing from a jump. The height and arc of the jump affect the degree of toe first landing. Besides bypassing the heel's shock absorbing function, toe first landing has been shown to actually put more strain on the deep digital flexor tendon and navicular apparatus. The point of initial ground contact not only affects the foot, but also all the structures of the limb. A normal heel first landing puts a gradual increase in strain on the deep digital flexor tendon, whereas toe first landing puts abrupt high peak strains on the tendon, almost like a snapping action. Visualize a normal horse galloping, as the limb is fully extended the heel impacts the ground, as the horse's body passes over the limb (and the limb is now in the vertical position) the toe region sinks into the ground while the fetlock displaces downward (full extension of fetlock joint). This pattern slowly increases tension on the tendon; in fact as the limb is fully loaded the toe is sinking into the ground creating a heel wedge effect, which helps take some strain off of the tendon during this position. In a toe first landing pattern the toe would impact the ground, then as the body passes over the limb the heel rocks backward as the fetlock descends downward. This "out of phase rotation" of the distal interphalangeal and fetlock joints have been shown to put high strains on the deep digital flexor tendon and navicular apparatus.
>
> To minimize the occurrence of such injuries, the foot needs to be properly balanced and shod. When the foot is allowed to get out of balance causing abnormal weight distribution, the hoof capsule becomes distorted and susceptible to injury."

Proper trimming and shoeing are essential to help maintain foot balance. Typically a farrier relies solely on the outward appearance of the foot and experience to accomplish this task. Radiographs are an additional tool that can be employed to help understand the internal structures within the foot. Radiographs can provide a detailed image of the bone structures within the foot and their relationship with the outer hoof capsule. In doing such a study we can take certain measurements to help define and document the current balance of the foot, and possibly make changes to help improve the foot balance. This can often help re-establish the natural working mechanisms of the equine foot. The following radiograph studies demonstrate how we are able to achieve foot balance with the aid of the radiographs.

1) Palmar angle is the first of these measurements to be evaluated. Palmar angle is the angle in which the coffin bone (bone inside the hoof) makes with the ground surface.

2) Sole depth is also measured and considered important, sole depth is a measurement of the depth of sole beneath the coffin bone.

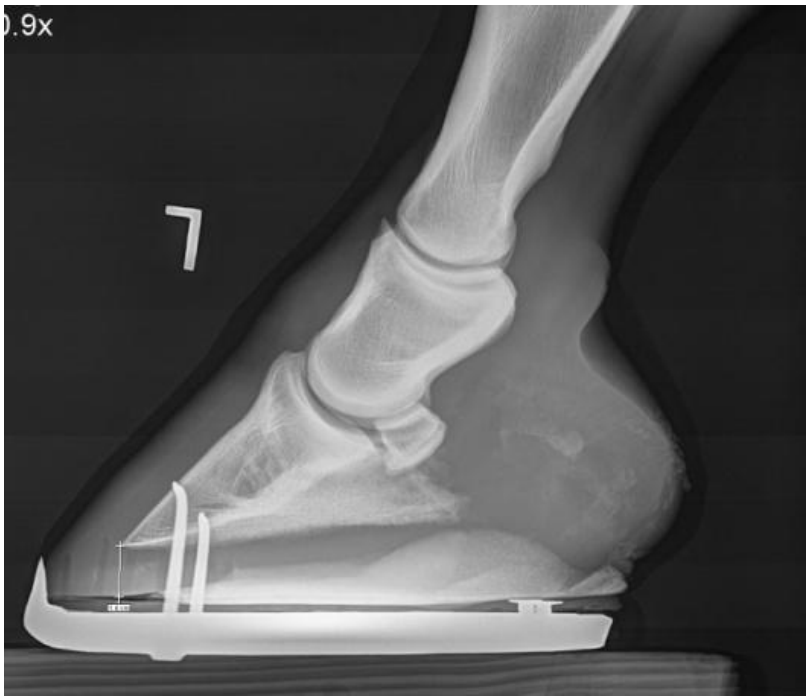

3) Break-over point is also measured and helps to define the toe length present. The break-over measurement is the distance from the tip of the coffin bone to the point on the shoe that is not in contact with the ground.

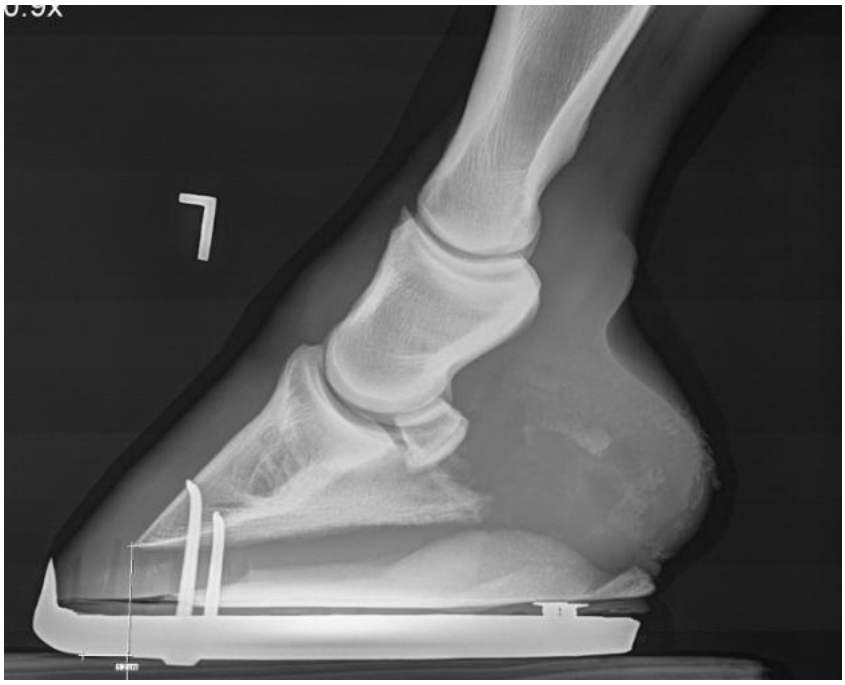

4) The toe to foot ratio, which is the percentage of toe length to the overall foot length centered on the center of articulation of the coffin joint.

Performing such a study, especially with horses which do not have ideal hoof conformation can be very valuable in maintaining soundness. Balancing the foot structures allows the foot to function in a normal manner. As the saying goes “an ounce of prevention is worth a pound of cure.”